

## Histological Characteristics of Abnormal Protrusions on Copepods from Lake Michigan, USA

Gretchen A. Messick<sup>1,\*</sup>, Henry A. Vanderploeg<sup>2</sup>, Joann F. Cavaletto<sup>2</sup> and Suzanne S. Tyler<sup>1</sup>

<sup>1</sup>National Oceanic and Atmospheric Administration, National Ocean Service, Cooperative Oxford Laboratory, Oxford, MD 21654-9724, USA

<sup>2</sup>National Oceanic and Atmospheric Administration, Great Lakes Environmental Research Laboratory, Ann Arbor, MI 48105, USA

(Accepted February 4, 2004)

**Gretchen A. Messick, Henry A. Vanderploeg, Joann F. Cavaletto and Suzanne S. Tyler (2004)** Histological characteristics of abnormal protrusions on copepods from Lake Michigan, USA. *Zoological Studies* 43(2): 314-322. Abnormal protrusions have been observed on crustacean zooplankton species from Lake Michigan since 1994. Copepods collected from 1994 to 2000 were assayed for the prevalence of protrusions, and histologically characterized for various morphologies. Protrusions occurred more frequently on nauplii than on copepodites or adults. Most protrusions were located laterally on the copepod body. External shapes and surfaces of the protrusions varied from smoothly rounded to bossulated and amorphous. Protrusions had diverse histological characteristics. Necrotic tissue was present in 58% of protrusions. Some protrusions had hyaline, crystal-like structures either on the surface or embedded within tissues of the protrusion. Nearly 40% contained what appeared to be herniated host tissue. A few copepods (3%) had elongated, symmetrical, somewhat transparent gross protrusions that were histologically identified as ellobiopsid parasites. Other protrusions had a histology that suggested ellobiopsid parasites such as a bossulated, bud-like external morphology or a smoothly rounded covering. Additionally, round structures observed within protrusions were similar to sporulation bodies of ellobiopsid parasites. It is unlikely that these protrusions were due to fixation artifacts or were caused by diatoms puncturing copepods in the collection devices. A few protrusions were obvious ellobiopsid parasites, but the histology of most protrusions is not consistent or obvious enough to allow identification of a plausible etiological agent. <http://www.sinica.edu.tw/zool/zoolstud/43.2/314.pdf>

**Key words:** Cyclopid, Calanoid, Ellobiopsid, Herniated, Necrotic.

Protrusions, also called tumor-like abnormalities, on several copepod species are considered a serious emerging threat to the well-being of the food web in Lake Michigan and other Great Lakes in the USA and Canada. The frequency of protrusions among species in the Great Lakes region ranged from 0% to 70% (Omair et al. 1999). Protrusions with a similar gross appearance have appeared on copepods from a small inland lake in Michigan (Bridgeman et al. 2000), Lake Maggiore, Italy (Manca et al. 1996), the Mediterranean Sea (Crisafi and Crescenti 1975), and the Gulf of Finland (Silina and Khudolei 1994). The histology of necrotic herniated protrusions on copepods from Lake Michigan has been described (Omair et al. 2001) as well as a brief histologic description

given of an ellobiopsid parasite on copepods with cysts from a small inland lake in Michigan (Bridgeman et al. 2000). The purposes of the current study were to describe the various histological characteristics of protrusions on copepods from Lake Michigan; to assay the prevalence of these characteristics; to assay whether the prevalence varies among collection date, season, or life stage; and to define an etiological agent.

### MATERIALS AND METHODS

Copepods were collected by duplicate tows of a 0.5-m-diameter, 153- $\mu$ m-mesh plankton net towed vertically from 2 m off the bottom to the sur-

\*To whom correspondence and reprint requests should be addressed. Tel:410-226-5193. Fax:410-226-5925. E-mail: Gretchen.Messick@NOAA.gov

face along different depth contours in Lake Michigan. Biweekly to monthly collections were made at 15, 45, and 110 m sites off Muskegon (43°11.29'N) and at 10, 15, 30, 45, 73, and 80 m sites off St. Joseph (42°11.73'N), Michigan during 1998-2000. From 1994 through 1997, zooplankton were collected at the 110 m site only. Immediately after collection, zooplankton were narcotized in club soda (carbonated water) and placed in 2%~4% sugar formalin (Haney and Hall 1973) or Bouin's fluid (Howard and Smith 1983) for preservation. In the laboratory, subsamples of zooplankton were taken with a Stempel pipette. Sufficient zooplankton were counted until at least 600 animals were identified. All adult copepods were identified to species and immature copepodites to genus, while nauplii were combined into 1 group using the key of Wilson and Yeatman (1959). We did not distinguish between calanoid and cyclopoid nauplii. Animals that appeared abnormal or subsamples of abnormal animals were sent to the Cooperative Oxford Laboratory (Oxford, MD) for histological analysis.

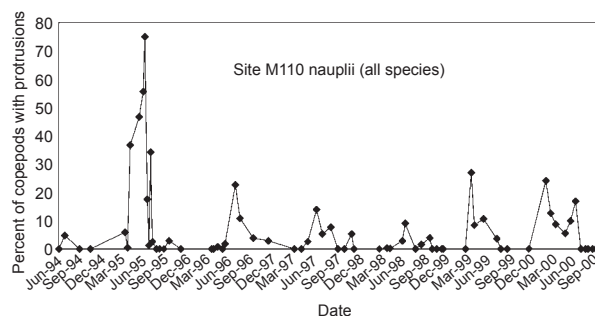
The diminutive nature of the copepods required that they initially be stained with eosin or rose Bengal to allow visualization while handling. Copepods were individually photographed, then stabilized in a histogel pellet and chilled to maintain the same orientation as when photographed. To prevent loss of specimens during histological processing, each gel pellet containing a copepod was put in a small mesh biopsy cassette, then placed within a routine histology cassette. Copepods were dehydrated and infiltrated with paraffin during a 1 hour processing. Caution was taken to allow copepods to remain in the paraffin bath for no longer than 15 min due to possible heat damage (Barszcz and Yevich 1976). Paraffin-infiltrated copepods were placed in a mold and embedded in a paraffin block. Copepods were serially sectioned at 4 to 5  $\mu\text{m}$  thickness, mounted on glass slides, and stained for 10 min each in Mayer's hematoxylin and eosin (MHE&E; Howard and Smith 1983). Copepod sections were observed at 400X~1000X with a light microscope.

Categories were assigned to groups based on the different locations where the protrusions were found on the copepod body, on the gross appearance of the protrusions, and on the histological characteristics of the protrusions. Categories for location of protrusions on copepods included the anterior, posterior, lateral, dorsal, and ventral positions. Categories for gross appearance of protrusions included bossulated, grainy, smooth, elongated

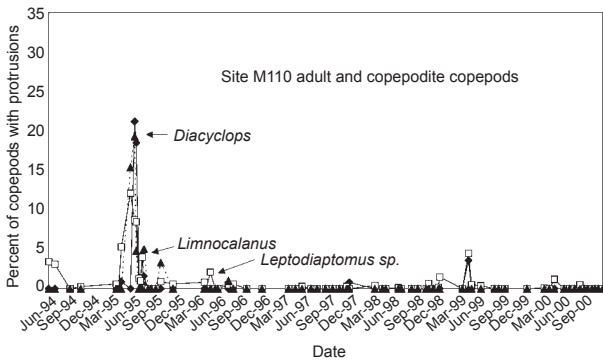
transparent, and containing glass-like rods. Categories for histological characteristics of protrusions included necrotic tissue, hyperchromatic cells, cells with diffuse nuclei, granular material, non-cellular material, herniated host tissue, lipid-like material, communication or channeling of tissue between the copepod and protrusion, glassy-like material, refringent specks, eosinophilic spheres, and obvious ellobiopsid-like structures. Some copepods had more than 1 protrusion, and some protrusions may have consisted of tissue or material that fell into more than 1 category. Chi-square analysis tested whether the occurrence of lateral protrusions was greater than expected by random chance and whether the proportion of protrusions varied significantly among calanoids, cyclopoids, and nauplii.

## RESULTS

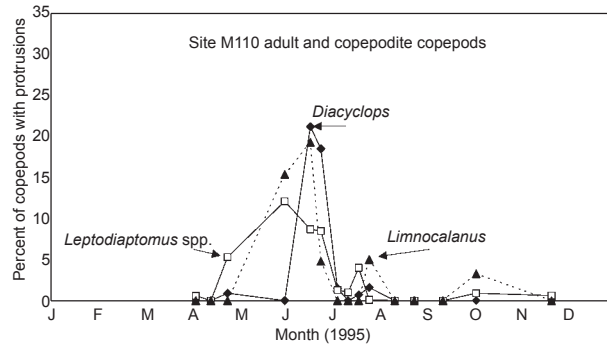
The prevalence of protrusions was highest in the early summer of 1995, higher in nauplii than in copepodites or adults, and generally higher during spring and early summer. At the 110 m site, for which we have the longest record, the highest frequency of protrusions occurred from late Apr. to July 1995 in all life stages of copepods collected (Figs. 1~3). Seventy-five percent of nauplii collected on June 29, 1995 had some sort of protrusion. During June and July 1995, the period of maximum protrusion occurrence, the proportion of copepods with protrusions varied significantly between copepods grouped as nauplii or adults, and among the copepodite *Diacyclops thomasi*, *Leptodiaptomus* sp., and *Limnocalanus macrurus* (Table 1). *Leptodiaptomus* spp. consisted of three species, *Leptodiaptomus ashlandi*, *L. sicilis* and *L. minutus*, that are commonly found in Lake



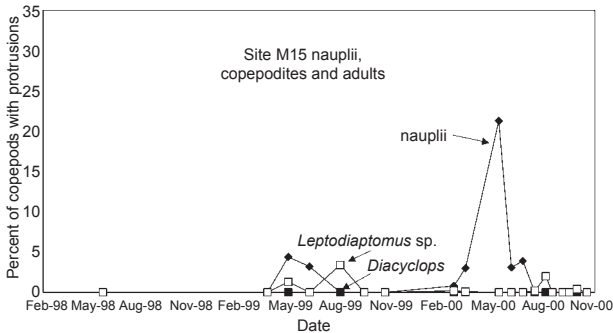
**Fig. 1.** Percent frequency of protrusions on nauplii collected from 110 m depth in Lake Michigan near Muskegon, MI from June 1994 to Sept. 2000. Calanoid and cyclopoid nauplii were not distinguished.



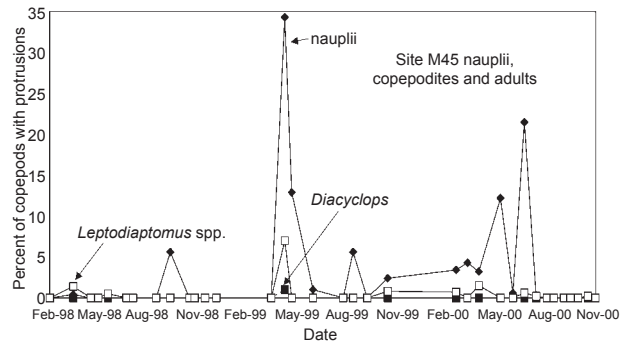
**Fig. 2.** Percent frequency of protrusions on adult and the copepodite cyclopoid *Diacyclops thomasi* and calanoids *Leptodiaptomus* spp. and *Limnocalanus macrurus* collected from 110 m depth in Lake Michigan near Muskegon, MI from June 1994 to Sept. 2000.



**Fig. 3.** Detailed view of percent frequency of protrusions on adult and copepodite cyclopoid (*Diacyclops thomasi*) and calanoid copepods (*Leptodiaptomus* spp. and *Limnocalanus macrurus*) collected from 110 m depth in Lake Michigan near Muskegon, MI in 1995, the period of highest occurrence.



**Fig. 4.** Percent frequency of protrusions on naupliar, adult, and copepodite cyclopoid *Diacyclops thomasi* and calanoid *Leptodiaptomus* spp. or *Limnocalanus macrurus* collected from 15 m depth in Lake Michigan near Muskegon, MI from Feb. 1998 to Nov. 2000.



**Fig. 5.** Percent frequency of protrusions on naupliar, adult, and copepodite cyclopoid *Diacyclops thomasi* and calanoid *Leptodiaptomus* spp. or *Limnocalanus macrurus* collected from 45 m depth in Lake Michigan near Muskegon, MI from Feb. 1998 to Nov. 2000.

**Table 1.** Number of copepods with protrusions ( $a_i$ ), number of copepods examined ( $n_i$ ), and proportion ( $p_i$ ) of copepods in different development stages or taxa with protrusions from 7 collections made at site M110 during June and July 1995, the period of maximum protrusion occurrence. Chi-square test showed that the proportions observed among groups significantly differed at the  $p < 0.005$  level

Variable	Nauplii	<i>Diacyclops</i>	<i>Leptodiaptomus</i> spp.	<i>Limnocalanus</i>	Total
$a_i$	746	164	251	12	1191
$n_i$	1928	2088	5764	149	9778
$p_i$	0.39	0.08	0.04	0.08	0.12

Michigan. The high frequency of occurrence in nauplii was obviously the source of variance among taxa. In all other years, no more than 30% of nauplii had protrusions at the 110 m site (Figs. 1-3). The highest occurrence of protrusions on *Diacyclops* (33%) occurred on June 22, 1995; after June 29, 1995 the occurrence of protrusions on *Diacyclops* was well below 5% of the population. High frequencies of protrusions also occurred on calanoid copepods (*Leptodiaptomus* spp. and *Limnocalanus*) during this period (Figs. 2, 3).

At the other Muskegon sites, M15 and M45, protrusions also occurred most often on nauplii. The highest rates occurred at M15 in Apr. 2000 (Fig. 4) and at M45 in May 1999 (Fig. 5). Less than 5% of adult and immature cyclopoid and calanoid copepods from M15 and M45 had protru-

sions (Figs. 4, 5).

The occurrence of protrusions on copepods from the St. Joseph sites, 96 km (60 mi) south of Muskegon, was relatively low, as was expected for the period 1998–2000. The highest rate of protrusion occurrence was 16% of *Leptodiaptomus* sp. in Mar. 1998 at the 10 m site. On the same day at the 73 m site, 7% of *Leptodiaptomus* sp. had protrusions. All other cases of protrusions on copepods from the St. Joseph region occurred on less than 1% of organisms on a given date and site, and most of the time no protrusions occurred.

The prevalence of gross characteristics reported here is for a subset of copepods selected for histological analysis because they had protrusions.

The prevalence of described characteristics does not reflect the prevalence in the population. The location of protrusions on analyzed copepods varied considerably. Fifty-six percent of protrusions occurred on lateral surfaces (Table 2). Many lateral protrusions originated from the prosome between the cephalosome and metasome. Bilateral protrusions generally erupted opposite each other on the same metasome (Fig. 6).

Categories for location were combined into lateral, dorsal/ventral, and anterior/posterior; some animals may have been included in more than 1 category. Lateral protrusions comprised 66%, dorsal/ventral 24%, and anterior/posterior 13% of the total. Chi-square analysis determined that the


**Table 2.** Prevalence of gross and histological protrusion characteristics in naupliar, copepodite, and adult calanoid and cyclopoid copepods sampled from 1995 to 2000 from various sites within Lake Michigan

Gross and histology	TLA description	All		Adult		Copepodite		Nauplii	
		#	%	#	%	#	%	#	%
gross	number of animals	188		15		9		81	
gross	no. protrusion	5	3						
gross	anterior	5	3	2	13	1	11	0	0
gross	posterior	13	7	1	7	0	0	6	7
gross	laterally on right side	56	30	1	7	0	0	31	38
gross	laterally on left side	48	26	2	13	0	0	23	28
gross	dorsal	24	13	1	7	2	22	4	5
gross	ventral	9	5	2	13	3	33	2	2
gross	attached	3	1						
gross	bossulated	85	45	0	0	0	0	39	48
gross	grainy	9	5	1	7	0	0	5	6
gross	smooth	50	27	1	7	3	33	27	33
gross	elongate transparent	6	3	0	0	0	0	1	1
gross	crystalline rods	5	3	0	0	0	0	1	1
histologically	no. protrusion	16	8.5	0	0	3	33	6	7
histologically	no. tissue	52	28	0	0	0	0	42	52
histologically	no. with protrusion in section	120							
histologically	necrotic	67	58	4	27	0	0	12	31
histologically	hyperchromatic cells	13	11	0	0	3	33	5	13
histologically	cells with diffuse nuclei	5	4	2	13	0	0	1	3
histologically	granular material	40	33	7	47	1	11	10	31
histologically	non-cellular material	19	16	3	20	0	0	6	15
histologically	herniated	47	39	1	7	2	22	20	51
histologically	host muscle	9	8						
histologically	host hemocytes	57	48	6	40	3	33	21	54
histologically	lipid-like material	22	18	3	20	0	0	0	0
histologically	communication between copepod and protrusion	21	18	0	0	1	11	3	8
histologically	glassy-like material	27	23	0	0	1	11	13	33
histologically	refringent specks	34	28	0	0	0	0	8	20
histologically	eosinophilic round bodies	9	8	1	7	0	0	2	5
histologically	ellobiopsid-like parasites	7	6	2	13	0	0	2	5


occurrence of lateral protrusions was greater than expected by random chance ( $\chi^2 = 30.6$ ;  $df = 2$ ;  $p < 0.001$ ).

Bossulated protrusions consisting of numerous raised knobby or bud-like protuberances along

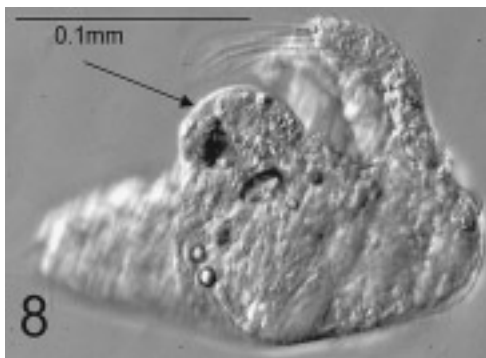
the outer periphery of the protrusion (Fig. 7) were found on 45% of affected copepods. Bossulated protrusions on nauplii could be 1/2 or more of the size of the entire affected copepod. Nauplii were found to have greater numbers of lateral and



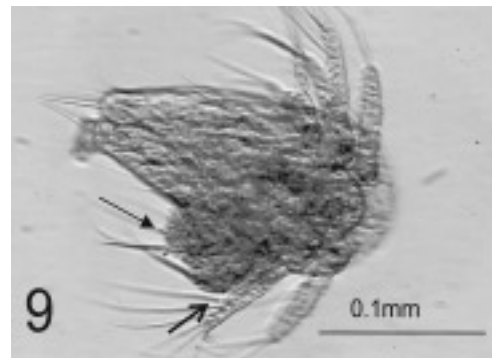
**Fig. 6.** A copepod with abnormal bilateral protrusions (arrows) projecting opposite each other from between the cephalosome and metasome. Line = 0.2 mm.



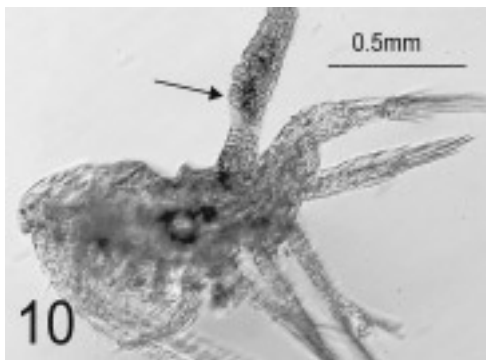**Fig. 7.** Naupliar stage copepod with a bossulated abnormal protrusion consisting of numerous raised knobby or bud-like protuberances (arrow) on the outer periphery of the protrusion. Line = 0.1 mm.



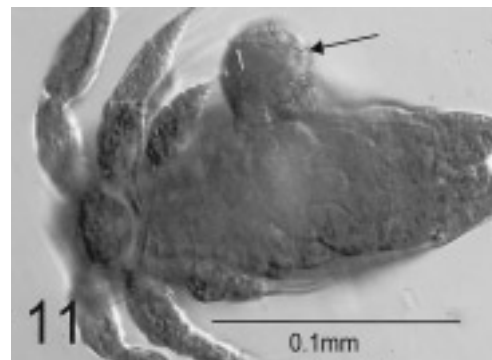**Fig. 8.** Naupliar stage copepod with an abnormal smooth protrusion with a translucent and rounded external surface and visible contents within its limiting membrane or smoothly rounded covering (arrow). Line = 0.1 mm.



**Fig. 9.** Naupliar stage copepod with a bossulated protrusion that appears as if its smooth covering (open arrow) has ruptured, released its contents, and formed a bossulated surface (closed arrow). Line = 0.1 mm.



**Fig. 10.** Copepod with a dorsal protrusion that is elongate and transparent with round bodies inside (arrow). This type of protrusion is very similar to ellobiopsid parasites containing round bodies that are spores at various stages of development. Line = 0.5 mm.



**Fig. 11.** Copepod with a lateral round protrusion with glassy or rod-like structures adhering to the surface of the protrusion (arrow) and that appear to adhere only to the protrusion. Line = 0.1 mm.

bossulated protrusions than did copepodites or adults (Table 2). Some copepods were not designated a life stage, so numbers of animals listed under nauplii, copepodites, or adults in table 2 might not equal the total animals assayed.

Protrusions categorized as smooth were found on 27% of analyzed animals. These usually had a translucent and rounded external surface with contents sometimes visible within a limiting membrane or smoothly rounded covering (Fig. 8). Some bossulated protrusions appeared as if they previously may have had a smooth covering that had ruptured, released the contents, and formed a bossulated surface (Fig. 9).

Grainy protrusions were found on 5% of analyzed copepods. The surface of these protrusions was finely granular and amorphous in shape. Grainy protrusions had a finer and less-uniform surface than did bossulated protrusions.

Three percent of analyzed copepods had elongated transparent protrusions. These protrusions occasionally contained variously sized round structures. Elongated transparent protrusions were very similar to those produced by ellobiopsisid parasites which often contain round bodies that are spores in various stages of development (Bridgeman et al. 2000) (Fig. 10). Elongated transparent protrusions were more abundant in the fall than in any other season, while winter abundance was higher than that in spring or summer.

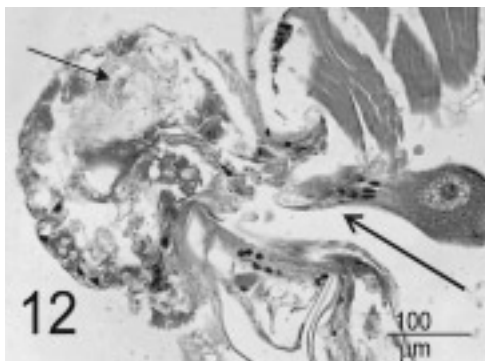
Glassy or rod-like structures on the surface of protrusions were seen on 3% of affected copepods. The rod-like structures seemed to adhere to the protrusion and aggregated there rather than on other parts of the copepod body (Fig. 11), although normal copepods without protrusions were

observed with glassy or rod-like structures interspersed among appendages.

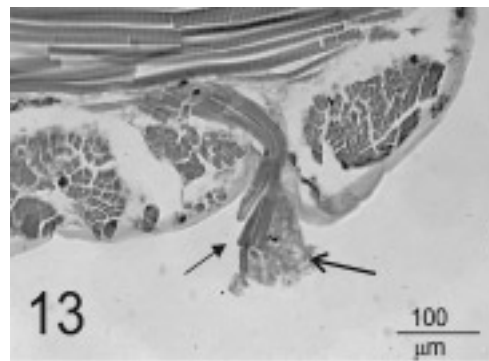
### Histological Characteristics

Only 120 of the initial 188 animals grossly observed were successfully processed to obtain accompanying histological sections. Some copepods lost their initial eosin or rose Bengal stain during dehydration and infiltration making it impossible to see them in the molten paraffin. Lack of staining and the small size sometimes made it difficult to obtain tissue sections oriented in a position which best demonstrated the histological characteristics of the copepod protrusion. In other situations, some sections did not reflect what was observed as the gross appearance of protrusions. The prevalence of histological characteristics includes only copepods that had tissue sections of protrusions on slides and does not reflect the actual prevalence in the population.

Necrotic tissue was present in 58% of copepod protrusions. Tissues were observed from the early stages of necrosis to late stages at which time tissues had little cell structure remaining. Hyperchromatic or pyknotic cells were present in 11% of protrusions, and cells with diffuse or enlarged pale-staining nuclei were found in 4% of protrusions. Tissue necrosis, pyknosis, and diffuse or enlarged pale-staining nuclei are histological characteristics indicative of irreversible cell injury or cell death. Protrusions that contained areas of finely granular, usually eosinophilic, material were found on 33% of copepods. Protrusions consisting of non-cellular material were found on 16% of copepods (Fig. 12).




**Fig. 12.** Histological section of a copepod with herniated necrotic tissue. The interior of the protrusion contains finely granular, non-cellular material (closed arrow). Internal host tissue appears to be channeling out to the protrusion (open arrow). Line = 100  $\mu$ m.



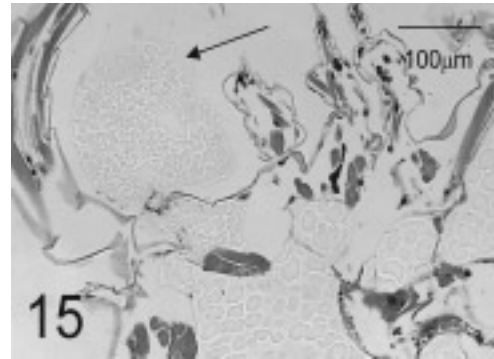
**Fig. 13.** Protrusion on a copepod consisting of herniated muscle tissue (closed arrow) along with finely granular, non-cellular necrotic material (open arrow). Line = 100  $\mu$ m.

Protrusions consisting of herniated tissue occurred on 39% of copepods. Host muscle projected from 8% of protrusions (Fig. 13), and host

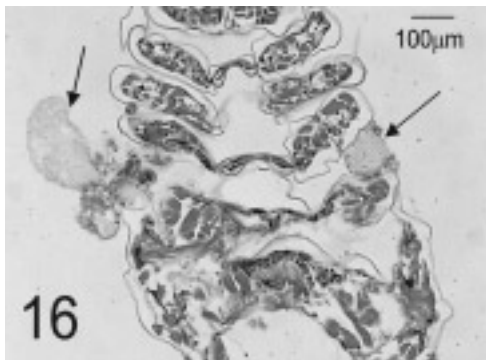


**Fig. 14.** Gross morphology of a protrusion projecting from the anterior of a copepod. The protrusion consists of faintly stained, finely granular, non-cellular lipid-like material. Line = 0.1 mm or 100  $\mu$ m.

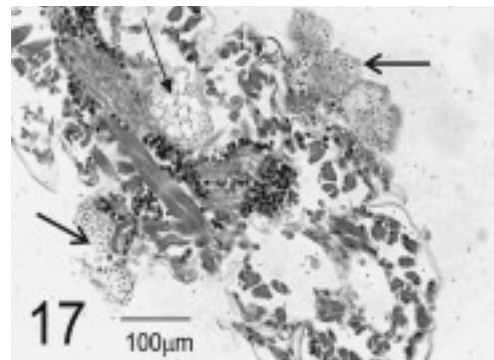
hemocytes were present in 48% of protrusions. Protrusions containing faintly staining, finely granular, non-cellular material were either obviously her-




**Fig. 15.** Histological morphology of the same copepod in fig. 14 showing that the protrusion consists of herniated, faintly stained, finely granular, non-cellular lipid-like material. Line = 100  $\mu$ m.



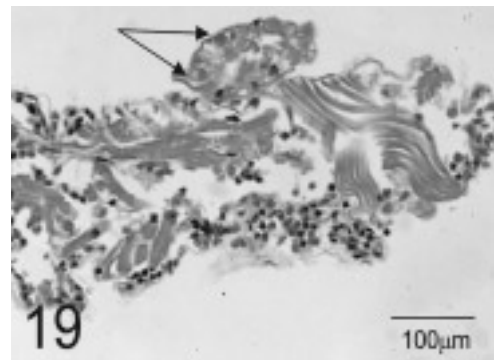
**Fig. 16.** Histological section of a copepod with bilateral protrusions consisting of lipid-like, non-cellular material. The protrusion on the right is between the somites. The protrusion on the opposite side of the same somite also consists of lipid-like material but has cellular material at its base. Line = 100  $\mu$ m.



**Fig. 17.** Histological section of a copepod with bilateral protrusions consisting of lipid-like, non-cellular material (open arrows). Round vacant areas inside the copepod are presumed to be where the lipid has dissolved from tissues due to histological solvents (closed arrow). Numerous refringent, acellular, darkly stained structures can be observed within the lipid-like material. Line = 100  $\mu$ m.



**Fig. 18.** Gross morphology of a protrusion with glassy, rod-like structures on a copepod. Line = 0.2 mm.



**Fig. 19.** Histological section of a copepod with a protrusion containing eosinophilic round bodies with no obvious nuclear material (arrows). These may be fruiting bodies of ellobiosid parasites. Smaller darker bodies are obvious nuclei. Line = 100  $\mu$ m.

niated from the body of the affected copepod (Figs. 14, 15) or appeared similar to lipids, with uniformly round vacant areas within a non-cellular matrix (Fig. 16). The prevalence of faintly staining, finely granular, non-cellular protrusions and lipid-like protrusions was 18%. Eighteen percent of protrusions had an obvious tissue connection or channeling of tissues such as gut or gonad between the protrusion and the copepod body. Refrangent, acellular, darkly staining small bodies were sometimes observed in the lipid sac and gut lumen of a few normal copepods assayed, and also in protrusions containing lipid-like material (Fig. 17); 28% of protrusions had these structures. Hyaline material that was non-cellular and amor- phously shaped was found within 23% of protrusions. Non-staining, round, glassy-like structures were found embedded within 23% of protrusions; these structures were consistent with those observed on the outer surface of protrusions as rods (Fig. 18).

Protrusions with eosinophilic round bodies containing no obvious nuclear material (Fig. 19) were found on 8% of copepods. These may have been fruiting bodies of ellobiopsid parasites (Bridgeman et al. 2000). Protrusions designated as ellobiopsid-like were found on 6% of copepods; these had histological structures closely resembling ellobiopsid parasites previously seen in fresh-water lake copepods (Bridgeman et al. 2000). Ellobiopsid-like protrusions were most often detected during winter months, and adult copepods had a higher abundance of ellobiopsid-like protrusions than did copepodites or nauplii.

Since the total sample size was only 188 animals, statistical analysis with ANOVA to compare collection date, season, and life stage with prevalence of protrusions among body location, gross appearance, and histology could not be carried out due to the large number of categories and lack of data or representation in some life stages, seasons, or collection dates.

## DISCUSSION

Abnormal protrusions on copepods had diverse histological manifestations. Numerous protrusions contained necrotic tissue that may have been caused by loss or restriction of blood supply to the tissue, exposure to the external environment, a lesion due to disease, or other types of local injury. Protrusions noted to contain granular material may have undergone autolysis, making

cells unidentifiable. Many herniated protrusions consisted of necrotic tissue or a combination of necrotic tissue and identifiable host tissue. Other researchers have concluded, based on examination of a few individuals, that protrusions are composed of apparently necrotic or degenerating tissues (Omair et al. 2001). Since copepods are small and were placed in fixative while still alive, we are confident that the fixative immediately penetrated and preserved tissues in their preexisting state. The presence of necrotic tissue indicates that copepods were traumatized before fixation, and therefore the lesions are not a fixation artifact. Also, if lesions had been induced during the collection process, they would not have had time to become necrotic.

The high rate of protrusions on nauplii as opposed to later life stages may partially be explained by their accelerated development and frequent molting into later naupliar and copepodite stages. Transitional molting stages in nauplii may predispose them to injury, developmental problems, or parasitism. The finding in this study that many protrusions projected from between somites may indicate that intersomite regions are more vulnerable to penetration or rupture than other areas. In a histological study of herniations through the body wall and cuticle of copepods, it was observed that the membrane in the intersomite region initially split, allowing a hernia to develop, rather than the intersomite membrane itself bulging along with the hernial sac and its contents (Omair et al. 2001). It appears that some element may sever the integumental membrane, thus allowing turgid internal tissue to expand outwards to the external environment where it becomes necrotic, possibly due to diminished blood flow or other factors. It is plausible that puncture wounds caused by external predators or parasites may initiate herniation (Bridgeman et al. 2000, Omair et al. 2001).

Some protrusions were obviously ellobiopsid parasites. Early life stages of ellobiopsid infestations are reported to attach to antennae and mouthparts of copepods (Jepps 1937), but infection mechanisms and histological characteristics of early infections were not described. Gross observations of ellobiopsid infections are similar to some of the histological characteristics found in this study. Jepps (1937) described bud-like sporulating parasites with granular and bossulated protrusions which are similar to the appearance of protrusions seen in this study. Jepps (1937) also described an ellobiopsid parasite with a rooted stalked attachment to antennae; this root had a "cuticular invest-



ment that becomes very thin towards its tip so that it is difficult to define." This may explain some of our difficulty identifying a root if ellobiopsid parasites were indeed causing a number of the protrusions whose etiological agent was not identified. The smoothly rounded covering found in this study may be similar to the test described by Jepps (1937) that degenerates after sporulating, then fills with debris, appears granular, and shows no sign of nuclear structures. Our study corroborates this by reporting that the smoothly rounded surface of some protrusions appeared to become bossulated. Additionally, 8% of protrusions in this study had eosinophilic round bodies with no obvious nuclear material. These structures may be similar to spore- or gamete-forming structures, trophomers, and gonomers that are described as granular material that occurs in spherical globules in ellobiopsid parasites (Boschma 1959). Adult copepods in the present study had a significantly higher prevalence of ellobiopsid-like parasites than did copepodites or nauplii (Table 2). It is plausible that an ellobiopsid parasite may infect nauplii and copepodites but does not manifest identifiable parasite histology until the parasite matures with the affected copepod at a later life stage. An additional conjecture is that the parasite's root-like attachment (Jepps 1937) punctures the integument, but failing to strongly attach, falls off, thus creating an outlet through which turgid tissue herniates.

The presence of crystal-like rods embedded in the surface of gross protrusions that histologically appear as non-staining glass-like structures is interesting. It seems plausible that the glass-like rods could puncture copepods causing herniation of host tissue. The question arises as to whether diatoms with sharp points concentrated with the collection method may have been present in samples and punctured the copepods which caused the internal tissue herniation. It is unlikely, however, that diatoms or collection debris would preferentially puncture copepods such that the location of protrusions on the copepod body was consistent or cause the symmetrical bilateral protrusions that were often found in this study.

We have not determined the etiologic agent(s) causing the abnormal protrusions on copepods from Lake Michigan. The protrusions are not due to fixation artifacts and are not likely caused by diatoms puncturing copepods in the collection devices. A few protrusions are ellobiopsid parasites; some have histological characteristics similar to those produced by ellobiopsid parasites, but these similarities are not convincing enough to

allow identification of an etiological agent. Copepods continue to be assayed to better define the histological characteristics of these protrusions and obtain a definitive cause for the abnormalities.

**Acknowledgments:** We thank Dorothy Howard of the Cooperative Oxford Laboratory for her assistance in obtaining histological copepod sections. From GLERL, we thank Megan Agy for identifying protrusions on copepods from St. Joseph and the crews of the RV *Shenehon*, RV *Lake Guardian*, and LV *Laurentian* for help with sample collections. We also thank Lee Hamilton, Jay Lewis, Jane Keller, Carol McCollough, and Dr. Kilho Park for kindly providing editorial assistance. This research project was supported by a grant from the US Environmental Protection Agency.

## REFERENCES

- Barszcz CA, PP Yevich. 1976. Preparation of copepods for histopathological examinations. *Trans. Am. Microsc. Soc.* **95**: 104-108.
- Boschma H. 1959. Ellobiopsidae from tropical West Africa. *Atl. Rep.* **5**: 145-175.
- Bridgeman TB, GA Messick, HA Vanderploeg. 2000. Sudden appearance of cysts and ellobiopsid parasites on zooplankton in a Michigan lake: or potential explanation of tumor-like abnormalities. *Can. J. Fish. Aquat. Sci.* **57**: 1539-1544.
- Crisafi P, M Crescenti. 1975. Conseguenze delle attivita umane sullo zooplankton del Mare di Taranto. *Boll. Pesca. Piscic. Idrobiol.* **30**: 207-218. (in Italian)
- Haney JF, DJ Hall. 1973. Sugar-coated *Daphnia*: a preservation technique for *Daphnia*. *Limnol. Oceanogr.* **18**: 331-333.
- Howard DW, CS Smith. 1983. Histological techniques for marine bivalve mollusks. Woods Hole, MA: US Dept. Commerce, NOAA Tech. Memo. NMFS-F/NEC. 25, 97 pp.
- Jepps MW. 1937. On the protozoan parasites of *Calanus finmarchicus* in the Clyde Sea area. *Q. J. Microsc. Sci.* **79**: 589-657 (plus unnumbered plates).
- Manca M, M Beltrami, D Sonvico. 1996. On the appearance of epibionts on the crustacean zooplankton of a large sub-alpine lake undergoing oligotrophication (L. Maggiore, Italy). *Mem. Ist. Ital. Idrobiol.* **54**: 161-171.
- Omair M, B Naylor, D Jude, J Quddus, T Beals, H Vanderploeg. 2001. Histology of herniations through the body wall and cuticle of zooplankton from the Laurentian Great Lakes. *J. Invertebr. Pathol.* **77**: 108-113.
- Omair M, A Vanderploeg, D Jude, G Fahnenstiel. 1999. First observation of tumor-like abnormalities (exophytic lesions) on Lake Michigan zooplankton. *Can. J. Fish. Aquat. Sci.* **56**: 1711-1715.
- Silina NI, VV Khudolei. 1994. Tumorlike anomalies in planktonic copepods. *Hydrobiologia* **30**: 52-55.
- Wilson MS, HC Yeatman. 1959. Free-living Copepoda. In WT Edmonson, ed. *Freshwater biology*. New York: J Wiley, pp. 735-861.